

# 2011 Colposcopic Terminology of the International Federation for Cervical Pathology and Colposcopy

Jacob Bornstein, MD, MPA, James Bentley, MB, ChB, Peter Bösze, MD, Frank Girardi, MD, Hope Haefner, MD, Michael Menton, MD, Myriam Perrotta, MD, Walter Prendiville, MD, Peter Russell, MD, Mario Sideri, MD, Björn Strander, MD, Silvio Tatti, MD, Aureli Torne, MD, and Patrick Walker, MD

New colposcopy terminology was prepared by the Nomenclature Committee of the International Federation of Cervical Pathology and Colposcopy after a critical review of previous terminologies, online discussions, and discussion with national colposcopy societies and individual colposcopists. This document has been expanded to

See related editorial on page 9.

*From the Nomenclature Committee of the International Federation for Cervical Pathology and Colposcopy, Department of Obstetrics & Gynecology, Western Galilee Hospital, and the Bar-Ilan University Faculty of Medicine, Nahariya, Israel; the Departments of Obstetrics and Gynecology, Dalhousie University, Halifax, Nova Scotia, Canada, Saint Stephen Hospital, Budapest, Hungary, L4000 Women's Hospital, the University of Michigan Hospitals, Ann Arbor, Michigan, the University of Sydney, Sydney, Australia, Institute of Clinical Sciences, Sahlgrenska Academy, Gothenburg University, Gothenburg, Sweden, and the Royal Free Hospital, London, United Kingdom; the Austrian Society of Colposcopy and Cervical Pathology, Vienna, Austria; the German Society of Colposcopy and Cervical Pathology, Reutlingen, Germany; the Gynecology Department, Lower Genital Tract Disease and Gynecologic Oncology Unit, Hospital Italiano de Buenos Aires, and the University of Buenos Aires, Buenos Aires, Argentina; the School of Medicine Hospital Italiano, Milano, Italy; the Beacon Hospital, Sandyford, Dublin, Ireland; Douglass Hanly Moir Pathology, Macquarie Park, New South Wales, Australia; the Preventive Gynecology Unit, Gynecology Division, European Institute of Oncology, Milan, Italy; and the Institut Clinic of Gynecology, Obstetrics and Neonatology, Hospital Clinic-Institut d'investigacions Biomediques August Pi I Sunyer (IDIBAPS), Faculty of Medicine-University of Barcelona, Barcelona, Spain.*

*The authors thank Drs. Alfonso Alba, Montserrat Cararach, Hanoch Levavi, Claudia Ester Marchitelli, Rami Mushonov, Olaf Reich, Eduardo Schejter, Efraim Stegler, Albert Singer, and Jeffrey Tan for providing useful comments during the discussions of the nomenclature committee.*

*Corresponding author: Jacob Bornstein, MD, MPA, Department of Obstetrics and Gynecology, Western Galilee Hospital, PO Box 21, Nahariya, 22100, Israel; e-mail: mdjacob@gmail.com.*

## Financial Disclosure

*The authors did not report any potential conflicts of interest.*

© 2012 by The American College of Obstetricians and Gynecologists. Published by Lippincott Williams & Wilkins.

ISSN: 0029-7844/12

include terminology of both the cervix and vagina. The popular terms “satisfactory colposcopy” and “unsatisfactory colposcopy” have been replaced. The colposcopic examination should be assessed for three variables: 1) adequate or inadequate, with the reason given; 2) squamocolumnar junction visibility; and 3) transformation zone type. Other additions were the localization of the lesion to either inside or outside the transformation zone and determinants of size as well as location of cervical lesions. Two new signs were included in the terminology—the “inner border sign” and “ridge sign.” The following definitions have been added: congenital transformation zone, polyp (ectocervical or endocervical), stenosis, congenital anomaly, and posttreatment consequence. In addition, the terminology includes standardization of cervical excision treatment types and cervical excision specimen dimensions. The International Federation of Cervical Pathology and Colposcopy recommends that the 2011 terminology replace all others and be implemented for diagnosis, treatment, and research.

(*Obstet Gynecol* 2012;120:166–72)

DOI: 10.1097/AOG.0b013e318254f90c

Since its description in 1925,<sup>1</sup> colposcopy has served as a tool that has helped in saving the lives of many women with cervical precancer and cancer. To describe and interpret the colposcopic findings, colposcopists use the terminology of the International Federation of Cervical Pathology and Colposcopy. The current nomenclature committee was established at the 2008 International Federation of Cervical Pathology and Colposcopy World Congress in Auckland, New Zealand. The committee examined the past three International Federation of Cervical Pathology and Colposcopy terminologies from 1975,<sup>2</sup> 1990,<sup>3</sup> and 2002<sup>4</sup> by reviewing publications that crit-



ically analyzed each colposcopic sign, aiming to create an evidence-based terminology.<sup>5-21</sup> The committee was chaired by Jacob Bornstein, MD, MPA, and was composed of 13 colposcopists from Argentina, Austria, Canada, Germany, Hungary, Ireland, Israel, Italy, Spain, Sweden, the United Kingdom, and the United States and one pathologist from Australia. The discussions were carried out through meetings, a dedicated web site, and e-mails. The terminology tables have been presented at several national and regional colposcopy congresses and on the International Federation of Cervical Pathology and Colposcopy web site ([www.ifcpc.com](http://www.ifcpc.com)). Criticisms from the International Federation of Cervical Pathology and Colposcopy-affiliated national societies and from individuals were discussed. The final terminology was reviewed and approved by all committee members, by the International Federation of Cervical Pathology and Colposcopy board, and finally by the International Federation of Cervical Pathology and Colposcopy general assembly at the World Congress in Rio de Janeiro on July 5, 2011.

As the representative body of the national societies of colposcopy and cervical pathology, the International Federation of Cervical Pathology and Colposcopy recommends that the 2011 terminology replace

all other terminologies and be implemented without delay for diagnosis, treatment, and research.

## THE STRUCTURE OF THE NEW NOMENCLATURE

The new nomenclature encompasses terminology related to the cervix and the vagina (Tables 1 and 2). Additionally, an addendum to terminology of the cervix is included (Table 3).

## GLOSSARY

In the glossary, only those terms that have been changed from the 2002 terminology are defined.

### 2011 COLPOSCOPIC TERMINOLOGY OF THE CERVIX: GENERAL ASSESSMENT

“Adequate or inadequate for the reason”: this should be the opening statement of every colposcopic examination. The examination may be inadequate because the cervix is obscured by inflammation, bleeding, or scarring.

Squamocolumnar junction visibility: the squamocolumnar junction may be completely visible when 360° of the squamocolumnar junction is seen and partially visible when most of the squamocolumnar junction is visible but a section of it is inside the

**Table 1. 2011 International Federation of Cervical Pathology and Colposcopy Colposcopic Terminology of the Cervix**

Section	Pattern
General assessment	Adequate or inadequate for the reason (eg, cervix obscured by inflammation, bleeding, scar) Squamocolumnar junction visibility: completely visible, partially visible, not visible Transformation zone types 1, 2, 3
Normal colposcopic findings	Original squamous epithelium: mature, atrophic Columnar epithelium; ectopy/ectropion Metaplastic squamous epithelium; nabothian cysts; crypt (gland) openings Deciduosis in pregnancy
Abnormal colposcopic findings	General principles Location of the lesion: Inside or outside the transformation zone; location of the lesion by clock position Size of the lesion: number of cervical quadrants the lesion covers Size of the lesion as percentage of cervix Grade 1 (minor): Fine mosaic; fine punctation; thin acetowhite epithelium; irregular, geographic border Grade 2 (major): Sharp border; inner border sign; ridge sign; dense acetowhite epithelium; coarse mosaic; coarse punctation; rapid appearance of acetowhitening; cuffed crypt (gland) openings Nonspecific: Leukoplakia (keratosis, hyperkeratosis), erosion Lugol's staining (Schiller's test): stained or nonstained
Suspicious for invasion	Atypical vessels Additional signs: fragile vessels, irregular surface, exophytic lesion, necrosis, ulceration (necrotic), tumor or gross neoplasm
Miscellaneous findings	Congenital transformation zone, condyloma, polyp (ectocervical or endocervical), inflammation, stenosis, congenital anomaly, posttreatment consequence, endometriosis



**Table 2. 2011 International Federation of Cervical Pathology and Colposcopy Clinical and Colposcopic Terminology of the Vagina**

Section	Pattern
General assessment	Adequate or inadequate for the reason (eg, inflammation, bleeding, scar) transformation zone
Normal colposcopic findings	Squamous epithelium: mature or atrophic
Abnormal colposcopic findings	General principles: Upper third or lower two-thirds Anterior, posterior, or lateral (right or left) Grade 1 (minor): Thin acetowhite epithelium, fine punctuation fine mosaic Grade 2 (major): Dense acetowhite epithelium, coarse punctuation coarse mosaic Suspicious for invasion: Atypical vessels Additional signs: fragile vessels, irregular surface, exophytic lesion, necrosis ulceration (necrotic), tumor or gross neoplasm Nonspecific: Columnar epithelium (adenosis) Lesion staining by Lugol's solution (Schiller's test): stained or nonstained, leukoplakia
Miscellaneous findings	Erosion (traumatic), condyloma, polyp, cyst, endometriosis, inflammation, vaginal stenosis, congenital transformation zone

endocervical canal or when a lesion covers the squamocolumnar junction with its inner border in the endocervical canal. The squamocolumnar junction may be not visible when all or most of the squamocolumnar junction cannot be seen because it is in the endocervical canal.

**ABNORMAL COLPOSCOPIC FINDINGS**

**Location of the Lesion Inside or Outside the Transformation Zone**

Location of the lesion is relative to the original squamocolumnar junction. "Inside" location means medial to the original squamocolumnar junction (toward the cervical os) and vice versa. The border of a lesion is a sharp border that is a straight edge of an acetowhite cervical lesion. Other edge definitions are

feathered or geographical margin, usually associated with a low-grade lesion, and rolled peeling edges that may be associated with a high-grade lesion.<sup>5,8</sup> The inner border sign<sup>22</sup> is a sharp demarcation between a thin and a dense acetowhite areas within the same lesion (Fig. 1). The ridge sign<sup>23</sup> is an opaque protuberance at the area of a white epithelium within the transformation zone (Fig. 2).

**MISCELLANEOUS FINDINGS**

**Posttreatment Effect**

This may or may not be an adverse feature: for example, stenosis, deformation or distortion, scarring, thickening or increased fragility of the mucosa, cervical endometriosis.

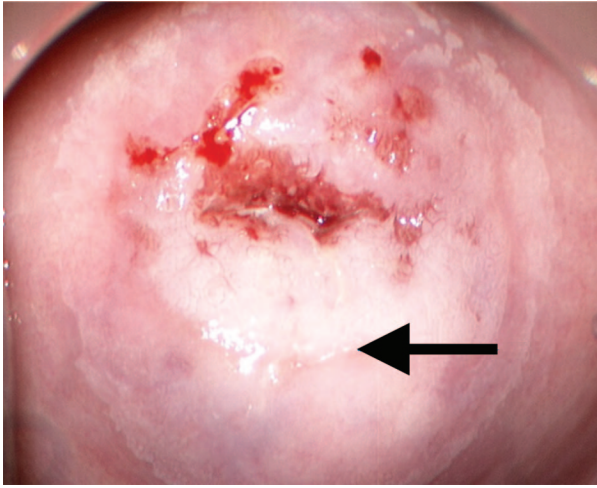
**Table 3. 2011 International Federation of Cervical Pathology and Colposcopy Colposcopic Terminology of the Cervix—Addendum**

Section	Pattern
Excision treatment types	Excision type 1, 2, 3
Excision specimen dimensions	Length—the distance from the distal or external margin to the proximal or internal margin Thickness—the distance from the stromal margin to the surface of the excised specimen. Circumference (optional)—the perimeter of the excised specimen

**2011 INTERNATIONAL FEDERATION OF CERVICAL PATHOLOGY AND COLPOSCOPY COLPOSCOPIC TERMINOLOGY OF THE CERVIX—ADDENDUM: EXCISION TREATMENT TYPES**

The excision types corresponding to the International Federation of Cervical Pathology and Colposcopy transformation zone-type classification describe three types of transformation zone mentioned in Table 1, which are classified according to the site, size, and visibility of the transformation zone. The excision itself may be carried out by any of the accepted methods: large loop excision of the transformation zone, which is identical to loop electrosurgical excision procedure, by needle excision of the transforma-





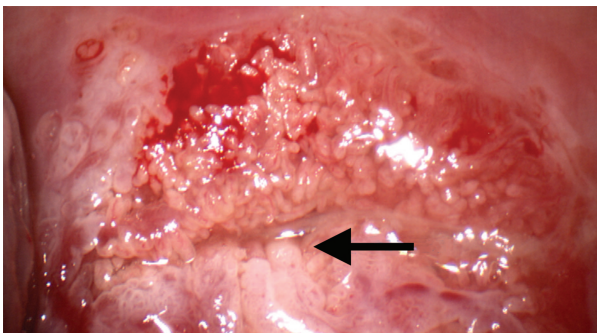
**Fig. 1.** Inner border sign. The *arrow* points to the sharp demarcation between thin and dense acetowhite areas that exists within the same lesion.

*Bornstein. Colposcopy Terminology. Obstet Gynecol 2012.*

tion zone, by straight wire excision of the transformation zone, or by cold knife conization. Type 1 excision resects a completely ectocervical or type 1 transformation zone. Type 2 excision resects a type 2 transformation zone. It will resect a small amount of endocervical epithelium that is visible with a colposcope. Type 3 excision (Fig. 3)- resects a type 3 transformation zone. It will resect a longer and larger amount of tissue than type 1 or type 2 excisions and will include a significant amount of endocervical epithelium. It may also be used to treat glandular disease or microinvasive disease or women who have had previous treatment.

### EXCISION SPECIMEN DIMENSIONS

Length is the distance from the distal or external margin to the proximal or internal margin of the



**Fig. 2.** Ridge sign. The *arrow* points to the opaque protuberance that is present at the area of a white epithelium within the transformation zone.

*Bornstein. Colposcopy Terminology. Obstet Gynecol 2012.*

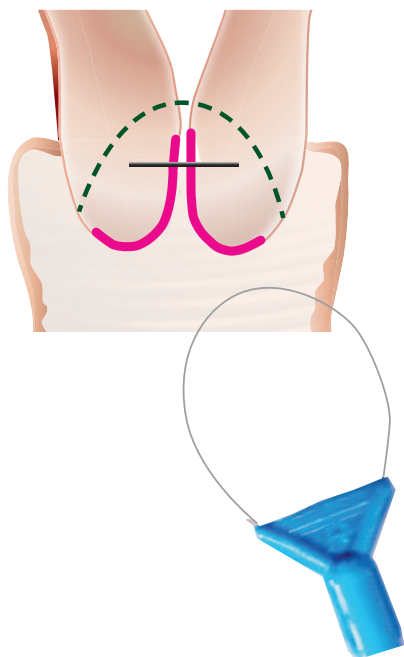
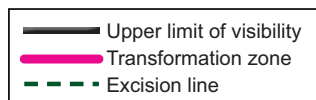
excised specimen (Fig. 4). Thickness is the distance from the stromal margin to the surface of the excised specimen. Circumference (optional) is the distance surrounding the perimeter of the excised specimen.

### DISCUSSION

The 2011 colposcopic terminology of the cervix table starts with “General Assessment.” This section replaces the 2002 nomenclature’s section IV,<sup>4</sup> which used the established term “unsatisfactory colposcopy.” Placing this section at the beginning of the cervix colposcopy terminology table serves to emphasize that the colposcopic examination should start with a general assessment of the cervix to immediately recognize the level of reliability of the examination. The popular terms “satisfactory colposcopy” and “unsatisfactory colposcopy” were abandoned, because they have the connotation of an inadequate examination that needs to be repeated. Instead, the colposcopic examination is now assessed by three variables. The first is the “adequate or inadequate for the reason...” in which the cause of inadequacy should be explained; for example, the cervix is obscured by inflammation, bleeding, or scarring. The second variable is “squamocolumnar junction visibility,” which can be described as “completely visible,” “partially visible,” or “not visible.” The reason that the visibility and site of the squamocolumnar junction are so important is that it dictates both the ability to do a satisfactory examination and, when treatment is indicated, the extent and type of excision (as described later). The terms “adequacy” and “squamocolumnar junction visibility” are not mutually exclusive. For example, the squamocolumnar junction may be “partially visible” because a portion of its inner margin is located high in the endocervical canal, whereas the test is still “adequate” because the cervix itself is not obscured by blood or inflammation. The third parameter in that section, which was already included in the 2002 International Federation of Cervical Pathology and Colposcopy nomenclature, involves assigning a transformation zone type.<sup>4</sup> It overlaps to some degree, but not completely, with the visibility of the squamocolumnar junction. The transformation zone and the squamocolumnar junction are not the same thing; the squamocolumnar junction is the “inner” margin of the transformation zone. Both types 1 and 2 transformation zone are “completely visible,” but the differentiation between the two may be important, mainly for planning treatment.

In the “abnormal colposcopic findings,” we added the localization of the lesion to either inside or outside the transformation zone. The localization of the lesion in relation to the transformation zone was



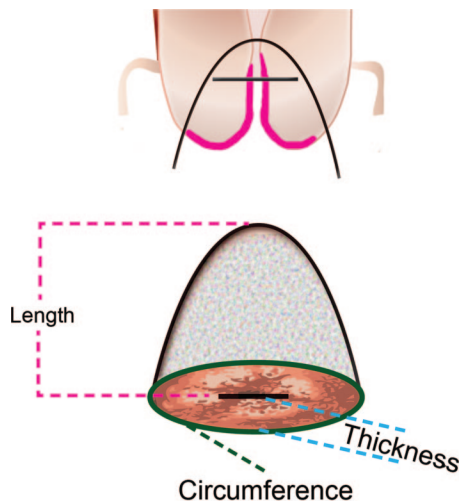


**Fig. 3.** Type 3 excision. Resection of a type 3 transformation zone. It includes a longer and larger amount of tissue than type 1 or type 2 excisions and a significant amount of endocervical epithelium.

*Bornstein. Colposcopy Terminology. Obstet Gynecol 2012.*

part of the 1990 International Federation of Cervical Pathology and Colposcopy colposcopic terminology<sup>3</sup> but not the 2002 terminology.<sup>4</sup> However, a lesion within the transformation zone, as opposed to one outside, since has been shown to be an independent predictor of a high-grade lesion or carcinoma (odds ratio 8.60, 95% confidence interval 1.2–63.4).<sup>5</sup>

The size of the cervical lesion was not included in the 2002 International Federation of Cervical Pathology and Colposcopy colposcopic terminology but has been found to have a predictive value for a high histologic grade (odds ratio 3.6, 95% confidence interval 2.1–6.3).<sup>19,21</sup> Therefore, several determinants of size as well as of location of cervical lesions were included for the first time in International Federation of Cervical Pathology and Colposcopy terminology: the number of cervical quadrants the lesion covers, size of the lesion as a percentage of the cervix, and location of the lesion by clock position(s). All three parameters were incorporated into the terminology because the parameters of size and location do not



**Fig. 4.** Line drawing of large loop excision of the transformation zone specimen after removal, with dimensions used to designate thickness, length, and circumference.

*Bornstein. Colposcopy Terminology. Obstet Gynecol 2012.*

overlap; for example, a lesion can occupy three quadrants but be composed of a thin layer of abnormal epithelium that occupies only 5% of the cervix. It may extend from the 2 o'clock to the 8 o'clock positions. Introduction of the two new signs, “inner border sign” and “ridge sign” to the grade 2 (major lesions) section, was the result of their significant validity as markers of high-grade cervical intraepithelial neoplasia.<sup>22,23</sup> Sharp border has also been associated with a more severe lesion. The term leukoplakia or keratosis was considered a major lesion in the first and second International Federation of Cervical Pathology and Colposcopy terminologies<sup>2,3</sup> but was reclassified in 2002 in the third International Federation of Cervical Pathology and Colposcopy terminology,<sup>4</sup> under “miscellaneous findings,” to diminish its significance. However, because leukoplakia or keratosis was shown to have a 25% independent predictive value of containing high-grade or invasive neoplasia,<sup>5</sup> we returned it to the abnormal colposcopic finding section, but to the nonspecific category, because it may represent either a benign or a severe intraepithelial lesion. Moving the test of Lugol’s staining (Schiller’s test) from the “minor grade” category to the “nonspecific” category of the “abnormal colposcopic findings” section is because several studies such as those associated with the ASCUS-LSIL Triage Study showed poor reliability of Lugol’s staining.<sup>14,24,25</sup> A cervical polyp is a common finding and has remained in the “miscellaneous findings,” including its origin as being ectocervical or endocervical.



## 2011 International Federation of Cervical Pathology and Colposcopy Colposcopic Terminology of the Cervix—Addendum

The reason for adding an “excision treatment types” addendum (although it is not a colposcopic pattern recognition issue) is to avoid using the terms: “conization,” “cone biopsy,” “big loop excision,” and “small loop excision.” Each of these may mean different things to different health care providers, whereas using the new International Federation of Cervical Pathology and Colposcopy excision treatment types will standardize the description of excisions of the transformation zone. The excision of each of the transformation zone types is associated with a different technique as well as with altered risk of incomplete excision and subsequent morbidity. The rationale for inclusion of the excised specimen dimensions in the 2011 International Federation of Cervical Pathology and Colposcopy terminology is similar. Several studies have shown that the size of the excised specimen of the cervix has implications on future pregnancy outcome. Therefore, there is a need to standardize the description of the excised specimen dimensions. The committee recognized that there is a lack of consensus in the published literature concerning the terms “length,” “depth,” and “height” of the specimen. In some publications “length” means the distance from the ectocervical margin to the endocervical margin. In other articles this parameter is termed “depth” or even “height.” To clarify this, the proposed terminology advises abandoning the terms “depth” and “height” and instead proposes the terms “length” and “thickness.” When multiple excision specimens are obtained, as is the case with an endocervical top-hat specimen, each specimen will be measured separately.

## 2011 International Federation of Cervical Pathology and Colposcopy Clinical and Colposcopic Terminology of the Vagina

The current nomenclature committee is the first that presents an International Federation of Cervical Pathology and Colposcopy terminology dedicated to colposcopy of the vagina. Various human papillomavirus lesions and intraepithelial neoplasia may occur in the vagina as a primary lesion or in continuum with cervical intraepithelial neoplasia. Although a transformation zone may occur, for example in diethylstilbestrol-exposed patients, where islands of columnar epithelium may be found within the squamous epithelium (adenosis), the cervical transformation zone types are irrelevant in the vagina.

## REFERENCES

1. Possibility of improving the inspection of the Vulva, vagina and cervix. *Munch Med Weekly Magazine* 1925;77:1733.
2. Staff A. New nomenclature for colposcopy. Report of the Committee on Terminology. *Obstet Gynecol* 1976;48:123–4.
3. Staff A, Wilbanks GD. An international terminology of colposcopy: Report of the Nomenclature Committee of the International Federation of Cervical Pathology and Colposcopy. *Obstet Gynecol* 1991;77:313–4.
4. Walker PG, Dexeus S, De Palo G, Barrasso R, Campion M, Girardi F, et al. International terminology of colposcopy: an updated report from the International Federation for Cervical Pathology and Colposcopy. *Obstet Gynecol* 2003;101:175–7.
5. Hammes LS, Naud P, Passos EP, Matos J, Brouwers K, Rivoire W, Syrjänen KJ. Value of the International Federation for Cervical Pathology and Colposcopy (IFCPC) Terminology in predicting cervical disease. *J Low Genit Tract Dis* 2007;11:158–65.
6. Seshadri V, O'Connor DM. The agreement of colposcopic grading as compared to directed biopsy results. *J Lower Gen Tract Dis* 1999;3:150–4.
7. Mitchell MF, Schottenfeld D, Tortolero-Luna G, Cantor SB, Richards-Kortum R. Colposcopy for the diagnosis of squamous intraepithelial lesions: a meta-analysis. *Obstet Gynecol* 1998;91:626–31.
8. Reid R, Scalzi P. Genital warts and cervical cancer. VII. An improved colposcopic index for differentiating benign papillomaviral infections from high-grade cervical intraepithelial neoplasia. *Am J Obstet Gynecol* 1985;153:611–8.
9. Mousavi AS, Fakour F, Gilani MM, Behtash N, Ghaemmaghami F, Karimi Zarchi M. A prospective study to evaluate the correlation between Reid colposcopic index impression and biopsy histology. *J Low Genit Tract Dis* 2007;11:147–50.
10. Seidl S. Reflections on the international colposcopic nomenclature. *Geburtshilfe und Frauenheilkunde* 2005;65:1028–30.
11. Bowring J, Strander B, Young M, Evans H, Walker P. The Swede score: evaluation of a scoring system designed to improve the predictive value of colposcopy. *J Low Genit Tract Dis* 2010;14:301–5.
12. Strander B, Ellström-Andersson A, Franzén S, Milsom I, Rådberg T. The performance of a new scoring system for colposcopy in detecting high-grade dysplasia in the uterine cervix. *Acta Obstet Gynecol Scand* 2005;84:1013–7.
13. Massad LS, Jeronimo J, Katki HA, Schiffman M; National Institutes of Health/American Society for Colposcopy and Cervical Pathology (NIH/ASCCP) Research Group. The accuracy of colposcopic grading for detection of high grade cervical intraepithelial neoplasia. *J Low Genit Tract Dis* 2009;13:137–44.
14. Ferris DG, Litaker MS; ALTS Group. Prediction of cervical histologic results using an abbreviated Reid Colposcopic Index during ALTS. *Am J Obstet Gynecol* 2006;194:704–10.
15. Ferris DG, Litaker M; ALTS Group. Interobserver agreement for colposcopy quality control using digitized colposcopic images during the ALTS trial. *J Low Genit Tract Dis* 2005;9:29–35.
16. Guido RS, Jeronimo J, Schiffman M, Solomon D, for the ALTS group. The distribution of neoplasia arising on the cervix: results from the ALTS trial. *Am J Obstet Gynecol* 2005;193:1331–7.
17. Massad LS, Jeronimo J, Schiffman M; National Institutes of Health/American Society for Colposcopy and Cervical Pathology (NIH/ASCCP) Research Group. Interobserver agreement



- in the assessment of components of colposcopic grading. *Obstet Gynecol* 2008;111:1279–84.
18. Pretorius RG, Zhang WH, Belinson JL, Huang MN, Wu LY, Zhang X, Qiao YL. Colposcopically directed biopsy, random cervical biopsy, and endocervical curettage in the diagnosis of cervical intraepithelial neoplasia II or worse. *Am J Obstet Gynecol* 2004;191:430–4.
  19. Shaw E, Sellors J, Kaczorowski J. Prospective evaluation of colposcopic features in predicting CIN: degree of acetowhite change most important. *J Low Genit Tract Dis* 2003;7:6–10.
  20. Sideri M, Spolti N, Spinaci L, Sanvito F, Ribaldone R, Surico N, Bucchi L. Interobserver variability of colposcopic interpretations and consistency with final histologic results. *J Low Genit Tract Dis* 2004;8:212–6.
  21. Kierkegaard O, Byrjalsen C, Hansen KC, Frandsen KH, Frydenberg M. Association between colposcopic findings and histology in cervical lesions: the significance of the size of the lesion. *Gynecol Oncol* 1995;57:66–71.
  22. Scheungraber C, Glutig K, Fechtel B, Kuehne-Heid R, Duerst M, Schneider A. Inner border—a specific and significant colposcopic sign for moderate or severe dysplasia (cervical intraepithelial neoplasia 2 or 3). *J Low Genit Tract Dis* 2009;13:1–4.
  23. Scheungraber C, Koenig U, Fechtel B, Kuehne-Heid R, Duerst M, Schneider A. The colposcopic feature ridge sign is associated with the presence of cervical intraepithelial neoplasia 2/3 and human papillomavirus 16 in young women. *J Low Genit Tract Dis* 2009;13:13–6.
  24. El-Shalakany AH, Saeed MM, Abdel-Aal MR, El-Nakeeb AH, Noseirat N, Avvad SB, El Din ZS. Direct visual inspection of the cervix with Lugol iodine for the detection of premalignant lesions. *J Low Genit Tract Dis* 2008;12:193–8.
  25. Rubio CA, Thomassen P. A critical evaluation of the Schiller test in patients before conization. *Am J Obstet Gynecol* 1976;125:96–9.



## Harold A. Kaminetzky Award

The American College of Obstetricians and Gynecologists (the College) and *Obstetrics & Gynecology* have established the Harold A. Kaminetzky Award to recognize the best paper from a non-U.S. researcher each year.

Dr. Harold A. Kaminetzky, former College Secretary and President, as well as Vice President, Practice Activities, has had a long career as editor of major medical journals. His last editorship was as Editor of the *International Journal of Gynecology and Obstetrics*. Dr. Kaminetzky has also had a long interest in international activities.

The Harold A. Kaminetzky Award winner will be chosen by the editors and a special committee of former Editorial Board members. The recipient of the award will receive \$2,000.

*Read the journal online at [www.greenjournal.org](http://www.greenjournal.org)*

1/2010

