

European guidelines for quality assurance in cervical cancer screening: recommendations for clinical management of abnormal cervical cytology, part 1

J. Jordan*, M. Arbyn[†], P. Martin-Hirsch[‡], U. Schenck[§], J-J. Baldauf[¶], D. Da Silva**, A. Anttila^{††}, P. Nieminen^{‡‡} and W. Prendiville^{§§}

*Birmingham Women's Hospital, Birmingham, UK, [†]Unit of Cancer Epidemiology, Scientific Institute of Public Health, Brussels, Belgium, [‡]Department of Obstetrics and Gynaecology, Royal Preston Hospital, Preston, UK, [§]Technical University, Munich, Germany, [¶]Department of Obstetrics and Gynaecology, Hôpitaux Universitaires de Strasbourg, Strasbourg, France, **Centro de Oncologica de Coimbra, Coimbra, Portugal, ^{††}Mass Screening Registry, Finnish Cancer Registry, Helsinki, Finland, ^{‡‡}Department of Obstetrics and Gynaecology, Helsinki University Central Hospital, Helsinki, Finland and ^{§§}Department of Obstetrics and Gynaecology, Coombe Women's Hospital, Dublin, Ireland

Accepted for publication 10 September 2008

J. Jordan, M. Arbyn, P. Martin-Hirsch, U. Schenck, J-J. Baldauf, D. Da Silva, A. Anttila, P. Nieminen and W. Prendiville

European guidelines for quality assurance in cervical cancer screening: recommendations for clinical management of abnormal cervical cytology, part 1

The current paper presents the first part of Chapter 6 of the second edition of *the European Guidelines for Quality Assurance in Cervical Cancer Screening*. It provides guidance on how to manage women with abnormal cervical cytology. Throughout this article the Bethesda system is used for cervical cytology terminology, as the European guidelines have recommended that all systems should at least be translated into that terminology while cervical intraepithelial neoplasia (CIN) is used for histological biopsies (*Cytopathology* 2007; **18**:213–9). A woman with a high-grade cytological lesion, a repeated low-grade lesion or with an equivocal cytology result and a positive human papillomavirus (HPV) test should be referred for colposcopy. The role of the colposcopist is to identify the source of the abnormal cells and to make an informed decision as to whether or not any treatment is required. If a patient requires treatment the colposcopist will decide which is the most appropriate method of treatment for each individual woman. The colposcopist should also organize appropriate follow-up for each woman seen. Reflex testing for high-risk HPV types of women with atypical squamous cells (ASC) of undetermined significance with referral for colposcopy of women who test positive is a first option. Repeat cytology is a second possibility. Direct referral to a gynaecologist should be restricted to special circumstances. Follow-up of low-grade squamous intraepithelial lesion is more difficult because currently there is no evidence to support any method of management as being optimal; repeat cytology and colposcopy are options, but HPV testing is not sufficiently selective, unless for older women. Women with high-grade squamous intraepithelial lesion (HSIL) or atypical squamous cells, cannot exclude HSIL (ASC-H) should be referred without triage. Women with glandular lesions require particular attention. In a subsequent issue of *Cytopathology*, the second part of Chapter 6 will be presented, with recommendations for management and treatment of histologically confirmed intraepithelial neoplasia and guidance for follow-up of special cases such as women who are pregnant, postmenopausal or immunocompromised.

Keywords: cervical cancer screening, clinical management, the Bethesda system, cervical intraepithelial neoplasia, colposcopy, European guidelines, human papillomavirus testing

Correspondence:

Joe Jordan, 20 Church Road, Edgbaston, Birmingham B15 3TA, UK.
Tel.: + 44 121 4542345; Fax: + 44 121 4545129;
E-mail: j.jordan@tiscali.co.uk

Introduction

An abnormal cervical cytology result indicates the possible presence of a progressive neoplastic lesion, which without treatment might evolve into a

life-threatening cancer. Nevertheless, a mild lesion is very likely to regress spontaneously, especially in young women, and therefore does not necessarily need treatment. The cytological suspicion of a high-grade lesion incurs a considerable risk of underlying severe dysplasia, which has a high chance of progression to cancer. These women should always be referred for colposcopy and biopsy. Appropriate treatment and/or follow-up must be offered based on the cytological, colposcopic and histological results and taking the particular clinical situation into account.

The paper starts with a description of the procedures used when a smear is abnormal; i.e. repeat cytology, human papillomavirus (HPV) testing, colposcopy, colposcopically directed punch biopsies or excision of the transformation zone (TZ). Endocervical evaluation by cytology or curettage is sometimes used when colposcopy is unsatisfactory or when an endocervical lesion is suspected. A special section deals with the technique, the interpretation and the terminology of colposcopy. In the final section, the procedures for each cytological category of the 2001 Bethesda system (TBS)^{1,2} are described. Recommendations are based on current knowledge of the natural history of lesions and available evidence concerning the accuracy of triage methods.

Diagnostic procedures for the evaluation of abnormal cytology

Repeat cytology

The cervical epithelium needs time to regenerate after cytology. Repeat cytology should not be performed < 3 months after a previous test. Repeating the cytology is an acceptable option when the report is atypical squamous cells of undetermined significance ASCUS (this term is used when referring to articles prior to TBS 2001), ASC-US,^{1,2} low-grade squamous intraepithelial lesion (LSIL) or unsatisfactory. In the latter case, it is useful for the laboratory to provide advice and sampling devices to the smear taker.³ Antimicrobial treatment is indicated before re-sampling if there is any suspicion of infection. Similarly, if the first smear was atrophic a second smear is recommended after topical oestrogenic treatment.

HPV testing

Recently, HPV DNA testing has been proposed as an alternative management option for women with

minor cytological lesions, allowing the clinician to select women needing colposcopic and histological assessment.^{4,5,6} When liquid-based cytology (LBC) is used, a reflex HPV DNA test can be performed using the residual liquid from the vial of women with an ASCUS result without the necessity to recall the woman. Nevertheless, HPV reflex testing can also be performed on a separately submitted specimen taken with a brush.

Colposcopy

In the context of a woman with an abnormal smear, the aims of colposcopy are:

1. To determine the precise geographical/anatomical position of the TZ.
2. To confirm or refute the cytological suspicion of cervical intraepithelial neoplasia (CIN).
3. To recognize or rule out invasive cancer.
4. To recognize or rule out glandular disease.
5. To facilitate treatment of and monitor progression or regression of CIN.

The colposcope was described first by Hinselmann.⁷ The modern colposcope is more sophisticated than that described by Hinselmann, but its basic principle remains the same, namely that it allows the cervix to be viewed at magnifications between 6× and 40×.

Colposcopy is used for three purposes:

1. To assess women with abnormal cervical cytology.
2. To assess women with a clinically suspicious cervix.
3. As a basic screening tool at the time of gynaecological examinations: this is how it was used by Hinselmann and it is still used in this way in some countries in Europe and Latin-America, usually in conjunction with cervical cytology. Colposcopy used in this way has a relatively high sensitivity for detecting premalignant disease, but its specificity is too low for the purpose of population screening.

The transformation zone. The TZ is that part of the cervix which in fetal life was covered by columnar epithelium but which by process of metaplasia becomes squamous. This is a normal phenomenon that occurs in every woman. The area of columnar epithelium that is transformed to squamous by the process of metaplasia is referred to as the TZ. The stimulus to the process of metaplasia is vaginal pH. Under the stimulus of maternal oestrogen prior to

birth and then shortly after birth the process of metaplasia begins. It is then arrested until the woman reaches puberty, at which time, under the stimulus of her own oestrogen, the vaginal pH again becomes acid and any columnar epithelium exposed to the vaginal acidity is transformed by metaplasia to new squamous epithelium. The importance of the TZ is that it is here that CIN develops, which if not detected and removed may progress to invasive squamous carcinoma. The TZ is easy for the colposcopist to identify due to the presence of Nabothian cysts or follicles, gland openings, and typical branching vessels.

Technique of colposcopy. After due counselling, the woman adopts the modified lithotomy position. After macroscopic (naked eye) examination of the vulva, a vaginal speculum is inserted to allow exposure of the cervix. The size of the speculum used will depend on the anatomy of the vagina. The cervix is washed with normal saline, thereby removing any excess mucus, blood or vaginal discharge. At this stage the use of a green filter will enhance the examination of the capillary angioarchitecture.^{8,9} A 3 or 5% solution of acetic acid is then applied to the cervix, following which any premalignant disease should appear 'aceto-white'. The degree of aceto-whiteness should be assessed after a minimum period of 20 s. Acetic acid causes tissue oedema and superficial coagulation of intracellular proteins, thereby reducing the transparency of the epithelium. When this happens the subepithelial capillaries are less easily visible and the epithelium itself appears white. The reason that colposcopy has a low specificity is that not all aceto-white epithelium is premalignant.

Aceto-white epithelium can be observed in the following situations:

1. Immature squamous metaplasia.
2. Healing or regenerating epithelium.
3. Congenital TZ.
4. HPV infection.
5. CIN.
6. A combination of CIN and HPV.
7. Cervical glandular intraepithelial neoplasia (CGIN).
8. Invasive squamous cell carcinoma.
9. Adenocarcinoma.

The colposcopist is taught to recognize original squamous epithelium, columnar epithelium, the squamocolumnar junction (SCJ) and the TZ. It is in the TZ that premalignant changes are found, and so it

is important for the colposcopist to identify, recognize and assess the TZ and decide whether it is normal or abnormal. The congenital transformation zone (CTZ) is that part of the cervix (and sometimes the vagina) that in fetal life was columnar epithelium but which during fetal life and immediately after birth becomes transformed from columnar epithelium to squamous epithelium by the process of metaplasia. The CTZ is sometimes difficult to recognize, but its characteristic features are that it is faintly aceto-white, is non-staining with iodine, and to the unwary eye can be confused with low-grade CIN or vaginal intraepithelial neoplasia (VAIN).

If the SCJ cannot be seen because the TZ extends into the endocervical canal, then an endocervical speculum should be inserted into the lower part of the endocervical canal to allow inspection. If the TZ can be seen in its entirety the colposcopy is graded satisfactory. If, on the other hand, the TZ cannot be seen in its entirety (because the SCJ extends into the endocervical canal beyond the reach of the colposcope) then the colposcopy is deemed unsatisfactory.

The application of Lugol's iodine (Schiller's test) causes a homogeneous dark brown staining of normal squamous epithelium. The principle behind this is that normal squamous epithelium is rich in glycogen, which stains brown with iodine. On the other hand, premalignant cells are deficient in glycogen and are therefore relatively non-staining. Iodine uptake gradation has been used for demarcating abnormal areas prior to treatment. However, most experienced colposcopists do not find any great benefit from the routine use of iodine. It should be remembered that not all non-glycogenated epithelium is abnormal: immature squamous metaplasia, healing/regenerating epithelium, CTZ and normal epithelium affected by HPV may also be non-glycogenated and therefore non-staining with iodine.

Note: A Schiller-positive test is an area which is non-staining with iodine!

Colposcopic features suggestive of CIN. There are changes in the subepithelial angioarchitecture that are apparent in premalignant disease. These can be summarized as follows:

1. Punctuation: either fine or coarse depending on the severity of the lesion.
2. Mosaic: either fine or coarse depending on the severity of the lesion.
3. Atypical vessels: suggestive of associated carcinoma.

4. The degree of aceto-whiteness: high-grade lesions are more densely aceto-white than low-grade lesions.
5. Borders of the lesion: low-grade lesions have feathery indistinct or finely scalloped edges, whereas high-grade lesions have sharp straight edges.

The colposcopic features of a low-grade lesion are: the lesion is faintly aceto-white; there may be no subepithelial vessels visible, but if the vessels are visible they take the form of a fine punctation or mosaic; and the lesion is non-staining with iodine. The colposcopic features of a high-grade lesion are: dense aceto-white changes, not staining with iodine, moderate or coarse punctation or mosaic and the presence of atypical vessels. If atypical vessels are very prominent and irregular, then the possibility of underlying malignancy should be considered. There is huge overlap between normal and abnormal epithelium for each of these indices of abnormality.

Colposcopic terminology. The International Federation for Cervical Pathology and Colposcopy (IFCPC) approved a revised colposcopic classification and basic colposcopic terminology in 2002 (see Table 1). As the primary organization of colposcopists and cervical cytologists, IFCPC recommended that this updated format be used for clinical diagnosis, treatment and research in cervical cancer.¹⁰

The new transformation zone classification. One of the most important recommendations in the new IFCPC classification was to define three types of TZ.^{10,11} The system has three indices by which the TZ may be classified (Table 2). These are:

1. the size of the ectocervical component of the TZ;
2. the position of the upper limit of the TZ; and
3. the visibility of the upper limit of the TZ.

The three types of TZ can be characterized as being completely ectocervical, fully visible with an endocervical component, or not fully visible (Figure 1). The qualification large or small refers to the ectocervical component of the TZ. Large means that the TZ occupies more than half of the ectocervical epithelium.

These three different TZ types warrant an individualized therapeutic approach. Even if one uses an excisional technique for every circumstance, it is still necessary to modify the approach according to the type of TZ. If one utilizes large loop excision of the TZ (LLETZ) as the routine treatment modality, the shape

Table 1. International Federation for Cervical Pathology and Colposcopy (IFCPC) classification for colposcopy¹⁰

I. Normal colposcopic findings
Original squamous epithelium
Columnar epithelium
Transformation zone
II. Abnormal colposcopic findings
Flat aceto-white epithelium
Dense aceto-white epithelium*
Fine mosaic
Coarse mosaic*
Fine punctation
Coarse punctation*
Iodine partial positivity
Iodine negativity*
Atypical vessels*
III. Colposcopic features suggestive of invasive cancer
IV. Unsatisfactory colposcopy
Squamocolumnar junction not visible
Severe inflammation, severe atrophy, trauma
Cervix not visible
V. Miscellaneous findings
Condylomata
Keratoses
Erosion
Inflammation
Atrophy
Deciduousis
Polyps

Table 1 is reproduced from ref. [10] with permission of the American College of Obstetricians and Gynaecologists.

*The characteristics of high-grade changes (dense aceto-white epithelium, coarse mosaic, coarse punctation, thick leukoplakia, atypical vessels); characteristics of low-grade changes are faint aceto-white epithelium, fine mosaic, fine punctation, thin leukoplakia.

and size of the loop needs to be modified according to the TZ type.

- *TZ type 1.* It is entirely appropriate to use either an excisional or destructive method, provided the standard criteria are met, in order to treat type 1 TZ successfully. For a small TZ a loop of 2 × 1.5 cm can be used, whereas for larger TZ a wider loop or a combination of loops should be chosen.
- *TZ type 2.* For a type 2 TZ it may be possible to use a destructive method, but we would advocate an excisional procedure: a 2 × 2 cm or larger loop excision if the TZ is small, a combination of loops if the TZ is large.
- *TZ type 3.* An excisional technique is mandatory for any type 3 TZ. The type 3 TZ has a high risk of

Type of TZ	Size	Site	Visibility	Adequacy colposcopy
Type 1	Small	Completely ectocervical	Fully visible	Satisfactory
Type 1	Large	Completely ectocervical	Fully visible	Satisfactory
Type 2	Small	Partially endocervical	Fully visible	Satisfactory
Type 2	Large	Partially endocervical	Fully visible	Satisfactory
Type 3	–	Totally endocervical	Not fully visible	Unsatisfactory
Type 3	Small	Partially endocervical	Not fully visible	Unsatisfactory
Type 3	Large	Partially endocervical	Not fully visible	Unsatisfactory

Table 2. Transformation zone geographical classification¹²

incomplete excision. In this circumstance it may be wise to consider alternatives to LLETZ. Straight wire excision is such an alternative, as are cold knife or laser excision.¹³

Diagnostic accuracy of colposcopy. Unbiased assessment of the sensitivity and specificity of a test requires the independent verification with a gold standard, which usually relies on histology. This is particularly difficult for colposcopy, since the choice of the biopsy site depends on colposcopy itself. Because of this intrinsic dependency, accuracy estimates for colposcopy are inflated. Colposcopically negative cases are very often considered as truly negative without histological confirmation. Moreover, in cases of glandular cervical lesions or endocervical location of the SCJ, colposcopy may be negative, even when intraepithelial neoplasia is present. In some cases the CIN can also be located in the gland clefts and may show a thin white rim around the gland opening (sometimes referred to as reverse mosaic or umbilicated mosaic). In a meta-analysis conducted by Mitchell,¹⁴ based on nine studies, the sensitivity and specificity of colposcopy in detecting

CIN2+ was estimated to be 96 and 48%, respectively. However, most studies included in the meta-analysis suffered from this bias.¹⁵ In one particular study conducted in Xanxi, China,¹⁶ a more unbiased assessment of colposcopic accuracy was revealed. Biopsy specimens were taken not only from colposcopically suspect areas but also from the four quadrants of the TZ in colposcopically negative cases. Also, endocervical curettage was performed in every woman. In this study the sensitivity of colposcopy-directed biopsy for CIN2+ in women with satisfactory colposcopy was 57% [95% confidence interval (CI) 52, 62].¹⁶

Colposcopic examination of the vagina and vulva. First, the vulva should be examined macroscopically. Inspection of the vaginal walls is part of a colposcopic examination. At completion of the colposcopic assessment of the cervix, the speculum should be withdrawn when the vaginal wall is being inspected. Any abnormalities may be identified and dealt with appropriately. If the cervical or vaginal surfaces look abnormal, then the vulva should be inspected colposcopically.

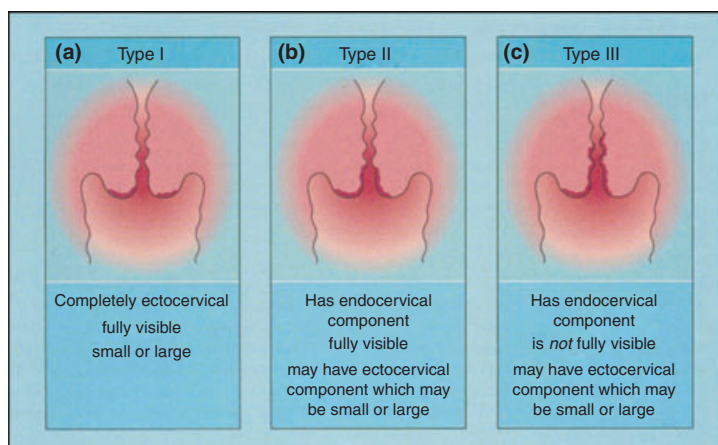


Figure 1. The three types of transformation zone, as proposed by the new International Federation for Cervical Pathology and Colposcopy classification.¹⁰

Colposcopy of the postmenopausal cervix. The postmenopausal cervix in women not using oestrogen replacement therapy may be atrophic. The cervical and vaginal epithelium becomes very thin, thereby allowing visualization of the subepithelial capillaries, which in turn may appear red and atypical. The use of acetic acid is not as effective in detecting premalignant disease in these cases. If there is any difficulty in assessing the postmenopausal cervix, it is helpful to give a short course (3–4 weeks) of intravaginal oestrogen cream.

Colposcopy in pregnancy and in the post partum period. The indication for colposcopy in pregnancy is an abnormal cervical smear. Again after due counselling, the colposcopic assessment proceeds in the same way as in the non-pregnant woman. Colposcopic assessment of the pregnant cervix is more difficult than in a non-pregnant cervix because the cervix is larger, oedematous and more vascular. An ordinary cervical speculum may make access to the cervix difficult, in which case a large speculum should be used. The cervix is usually covered by mucus, which is difficult to remove, and in the primiparous patient in particular there may be immature metaplasia, which can confuse the issue. Decidual changes of the cervical epithelium can mimic cancerous epithelium. In addition to all of these factors, the vascular changes associated with abnormality may be more pronounced, leaving the inexperienced colposcopist to conclude that the severity of the lesion may be more than it actually is.

A pregnant woman with an abnormal cervical smear should be assessed by an experienced colposcopist. If the colposcopist feels that there is any cytological or colposcopic suggestion of malignancy, then a colposcopically directed biopsy specimen or specimens should be taken, but in the absence of these features biopsy should be postponed until after pregnancy. Biopsy specimens taken in pregnancy are often accompanied by bleeding, and the sample itself is often unsuitable for good histological assessment. The cervix should be assessed with cytology and colposcopy at intervals of 3 months during the pregnancy, with final assessment being undertaken 3–4 months after delivery.

In the immediate puerperium, the cervix may also be difficult to assess. Prior to the first postnatal ovulation, particularly in the woman who is still breastfeeding, the cervix may appear atrophic, which makes both cytology and colposcopy much more

difficult. If this proves a problem for diagnosis, then a short course of vaginal oestrogen will be helpful. When there is no suspicion of malignancy, it is often prudent to wait until the oestrogenic state has returned to normal before undertaking colposcopy and/or treatment.

Conclusions for colposcopy

1. Colposcopy allows identification, localization and delineation of premalignant lesions of the cervix, vagina and vulva and directs the biopsy site.
2. In some countries, colposcopy is used as a screening tool but, because of its low specificity, it should not be used in primary screening, but reserved for those women who have been shown to have abnormal cervical cytology.
3. Colposcopy must be performed prior to treatment of CIN.
4. Colposcopy should be performed only by trained and experienced colposcopists.^{17–20}
5. Colposcopists should audit their work to confirm that the outcome of their colposcopic assessment and colposcopically directed treatment is in keeping with internationally agreed standards.
6. The colposcopic findings should be recorded in the patient's record.

Cervical biopsy

A cervical biopsy specimen is taken under colposcopic vision from the areas that reveal the highest degree of suspected abnormality.

A small sample can be taken with one of several specially designed cervical biopsy forceps. The colposcopist should ensure that the best possible sample is given to the pathologist. The biopsy specimen must include both the surface epithelium and the underlying stroma in order to decide whether the lesion is strictly intraepithelial or if it extends to the stroma. The specimen must include interpretable material, it must show no signs of thermocoagulation and it must be fixed rapidly. A punch biopsy specimen will often not be large enough to achieve sufficient depth whereby microinvasive disease can confidently be ruled out. Usually a local anaesthetic is not required, although there is evidence that local analgesia is effective in reducing discomfort associated with punch biopsies.²¹ If necessary, more than one biopsy specimen can be taken. A further technique for taking a small biopsy specimen is to use a small diathermy

loop, in which case local anaesthetic should be injected before taking the specimen: this technique has the advantage of giving a good specimen with an adequate amount of stroma and without distorting tissue.^{22,23} These biopsies are superior to punch biopsies for revealing or ruling out microinvasive cancer.²⁴ If bleeding occurs following the removal of the specimen then it can be arrested using either diathermy or simply applying Monsel's solution.²⁵ If endocervical material is required for histological examination, the colposcopist should take this using an endocervical curette or an endocervical brush.

The diagnostic quality of the histological examination of a biopsy may suffer from a number of imperfections. On the one hand, sampling error is a major cause for underreporting of lesions; on the other hand, subjectivity of histological interpretation adds to the limitations in reliability.^{26,27} More precise instructions on biopsy specimen taking, storage, transport, processing and examination are provided in the chapter on techniques and quality assurance guidelines for histopathology.²⁸

Endocervical curettage

Endocervical curettage (ECC) aims to detect an endocervical squamous or glandular lesion that cannot be reached by a colposcopically directed biopsy. The presence or absence of an invasive lesion cannot be confirmed because the specimen is often superficial. Moreover, ECC distorts the local architecture, compromising the distinction between adenocarcinoma *in situ* and invasive adenocarcinoma. Endocervical sampling using an endocervical brush shows a lower false-negative rate than ECC.^{29–32} In the USA, ECC is often carried out in conjunction with cervical biopsy. It is used less frequently in Europe, where more often a diagnostic conization is preferred when an endocervical lesion has to be excluded.³³ Endocervical curettage should not be performed during pregnancy.³⁴

Management of patients according to the severity of cytological abnormalities

In the next section, management procedures are proposed according to the type and severity of the reported cytological abnormalities. Management of histologically confirmed CIN will be addressed in the next section. The decision to treat and the choice of treatment must be based on the natural history of the

lesion,³⁵ and the probability of cytological sampling and/or interpretation error.³⁶ The approaches chosen to manage cytological abnormalities should make allowances for individual characteristics, such as age, fertility status and likely attendance for follow-up, risk profile and immune status.

Management of women with atypical squamous cells

Data providing evidence. Melnikow *et al.*³⁷ reviewed data published between 1970 and 1996, and pooled regression and progression rates, separated by a period of follow-up for each category of TBS 1991, using meta-analytical methods. The probability of progression of ASCUS to invasive disease over 6 months and to high-grade squamous intraepithelial lesion (HSIL) over 24 months was 0.06 and 0.25%, respectively. In the Norwegian screening programme, the relative risk of CIN2+ within 2 years after an ASCUS diagnosis compared with women with a negative result was 15 to 30.³⁸ In the ASCUS LSIL Triage Study (ALTS) trial, the 24-month cumulative incidence of CIN3+ among women with an index smear showing ASCUS varied between 8 and 9%.³⁹ In a meta-analysis of the diagnostic performance of management methods for women with a prior ASCUS result, the pooled prevalent risk of CIN2+ was 10% and the risk of CIN3+ was 6%.^{5,6} These data indicate that women with ASCUS need further evaluation.

In the above-mentioned meta-analysis of ASCUS triage, the pooled (cross-sectional) sensitivity of repeat cytology for the presence of histologically confirmed CIN2+, using ASCUS or worse as the positive triage result, was estimated to be 82% (95% CI 78, 84), whereas the pooled specificity was only 58% (95% CI 50, 66).⁵ The sensitivity of a repeat smear using LSIL or HSIL as the cut-off was substantially lower. The pooled sensitivity and specificity for CIN2+ of the Hybrid Capture 2 (HC2) assay for high-risk types of HPV was 95% (95% CI 93, 97) and 67% (95% CI 58, 76), respectively. The HC2 test positivity rate was 41% overall, and varied from 29⁴⁰ to 88%.⁴¹ The sensitivity ratio (sensitivity of repeat cytology at the threshold of ASCUS+/sensitivity of HC2) was 1.16 (95% CI 1.04, 1.29), indicating a sensitivity for HC2 being, on average, 16% higher than for repeat cytology. The specificity of HC2 was higher as well, but the difference was not significant (ratio of 1.05; 95% CI 0.96, 1.15). The relative accuracy of both triage strategies using CIN3+ as the outcome showed similar results as for CIN2+.⁶

In the ALTS study, the (longitudinal) sensitivity for a CIN3+ diagnosis within 2 years, using the HC2 assay at enrolment, was estimated at 92%. Fifty-three percent of women were HPV+ and were referred for colposcopy.³⁹ The longitudinal sensitivity of cytology repeated every 6 months for 2 years, using ASCUS as the cytology threshold, was similar, but in this strategy 73% of women required referral to colposcopy. Remarkably, immediate colposcopy showed a lower sensitivity for cumulative CIN3 than HC2.

Management options in case of ASC-US. Three options can be considered when the presence of ASC-US is reported: high-risk HPV (hrHPV) DNA testing, repetition of the smear, and referral for colposcopy. Reflex hrHPV DNA testing is the preferred option when LBC is used and HPV tests are available.^{5,34,42} HPV+ cases should be referred for colposcopic evaluation. HPV testing can be repeated after 12 months^{43–45} when no CIN is found on colposcopy and biopsy. hrHPV–women should be recommended to have an additional cytology test taken after 1 year.³⁴

A second acceptable option is a cytology test after 6–12 months. If it is negative then the woman can be referred back to a normal screening schedule. If the repeat test is again ASC-US then a repeat is recommended within the next 6–12 months, and if the further repeat smear is again ASC-US then the woman should be referred for colposcopy. If any of the follow-up smears is greater than ASC-US then referral for colposcopy is advised. National guidelines may vary slightly in this particular recommendation and, therefore, clinicians should be guided by their own guidelines.

Referral for immediate colposcopy is another alternative, which many experts consider to be over-management.^{46,47} It may be the preferred choice when poor follow-up compliance is suspected or when explicit risk factors are present. Immediate referral for colposcopy should be no more than a very low percentage of cases of ASC-US. If colposcopy does not show CIN, a repeat smear after 1 year is recommended.

For women with ASC-US who have clinical or cytological signs of atrophy, a repeat smear after a course of intravaginal oestrogen is recommended. When ASC-US is accompanied by excessive inflammation due to an infection, appropriate antimicrobial treatment is indicated before repetition of the smear. Pregnant women with ASC-US should be managed as non-pregnant women.

Management of atypical squamous cells, cannot exclude HSIL Women with atypical squamous cells, where the presence of HSIL is suspected (ASC-H), should be referred for colposcopy. When colposcopy is negative, and when a diagnosis of ASC-US is agreed after review of cytology, colposcopy and histology, a repeat smear at 6 and 12 months or hrHPV DNA test at 12 months is recommended.³⁴ Such cases should be discussed in a multidisciplinary meeting.

Management of women with LSIL

Data providing evidence The natural history of LSIL lesions is reviewed and summarized below.

Melnikow's meta-analysis showed that the progression of low-grade lesions increased significantly by length of follow-up.³⁷ For LSIL, the cumulative rate of progression to HSIL was 6.6% (95% CI 1.1, 12.1) after 6 months and 20.8% (95% CI 6.1, 35.6) after 24 months. Probably the best documented natural history of cervical dysplasia is the study of Holowaty *et al.*, who studied cohorts included in the Toronto cytological registry linked to the Ontario cancer registry.⁴⁸ It was estimated that within 24 months 44.3% (95% CI 43.0, 45.5) of mild dysplasia regressed to normal; 0.6% (95% CI 0.5, 0.7) progressed to CIN3 and 0.1% (95% CI 0.0, 0.1) to cancer, whereas over 10 years 87.7% of women showing mild dysplasia (95% CI 86.0, 89.5) became normal, 2.8% (95% CI 2.5, 3.1) progressed to CIN3 and 0.4% (95% CI 0.3, 0.5) to invasive cancer.

In a meta-analysis of studies examining triage of women with LSIL, the pooled sensitivity of repeat cytology was 92% (95% CI 84, 98) with a specificity of 42% (95% CI 27, 56).⁴⁹ The HC2 test showed a pooled sensitivity for CIN2+ of 95% (95% CI 91, 100) and a specificity of only 33% (95% CI 18, 48). The sensitivity and specificity ratios did not differ significantly from unity. Both triage methods showed low specificity. The hrHPV test positivity rate varied between 58%⁵⁰ and 88%⁵¹ and its pooled value was 77% (95% CI 67, 86). On average, among women with LSIL, 17% (95% CI 10, 23) have prevalent CIN2+ and 12% (95% CI 5, 19) prevalent CIN3+.

Several longitudinal studies, spanning 1–3 years' follow-up, indicate increased progression and decreased regression rates as well as shorter progression and longer regression duration in hrHPV+ LSIL patients compared with hrHPV– LSIL cases.^{52–56} In the ALTS trial, the 2-year cumulative incidence of CIN3 among women with LSIL varied between 14 and

18%.⁵⁷ One repeat Pap smear at cut-off ASCUS had a sensitivity of 91% and resulted in referral of 81% of women. Cytology repeated every 6 months over 2 years allowed detection of all cases of CIN3, but resulted in referral to colposcopy of 89% of women. One HC2 test for the detection of hrHPV types at enrolment showed a sensitivity of 95% and a referral rate of 85%.⁵⁷ An HC2 test 12 months after a first report of LSIL detected 92% of cumulative CIN3+ and was associated with a referral rate of 55%.⁴⁴

Further research is needed to identify more specific tools to distinguish LSIL women who are truly at risk for progressive lesions. HPV DNA typing, type-specific viral load, targeting essentially HPV16, presence of hrHPV RNA and other progression markers are potential candidates. Currently, evidence does not support any method as being optimal.

Management options in case of LSIL Two management options can be proposed for woman with LSIL: repetition of the cytology and referral for colposcopy. In most settings, hrHPV testing as an initial management option is not sufficiently selective.

Repetition of the Pap smear is an acceptable strategy. Observation tends to be the preferred management, particularly in young nulliparous women. The smear may be taken at 6-month intervals until two subsequent negative smears have been obtained, and referral for colposcopy is advised if one of the smears shows ASC-US or a more severe lesion. Potential loss to follow-up should be taken into account before choosing this option. Given the higher prevalence of high-grade CIN in case of LSIL compared with ASC-US, referral to colposcopy can be chosen as the preferred option.

When colposcopy is satisfactory and shows no lesions, a repeat smear or hrHPV DNA testing 12 months later is useful. The recommendations concerning the management of ASC-US cases in postmenopausal women and women with infection also apply if LSIL is present.¹⁹

Management of women with HSIL

Data providing evidence In Melnikow's meta-analysis, the probability of progression from HSIL to invasive cancer at 24 months was estimated to be 1.4% (0, 4.0).³⁷ The probability of regression was 35%. Holowaty found a cumulative progression to cancer after 2 years of 0.3 and 1.6% in women with, respectively, moderate or severe dysplasia. The 10-

year cumulative rates were 1.2% for moderate and 3.9% for severe dysplasia.⁴⁸ The rate of hrHPV-positivity in HSIL is, in general, > 90%, and may even reach 100% depending on the HPV testing system used.

Management options in case of HSIL. Referral for colposcopy and biopsy is the rule when a cytology test shows HSIL. Triage using repeat cytology or HPV DNA detection is not indicated. If colposcopy is satisfactory and biopsy rule out the presence of high-grade CIN, a review of cytology and histology is recommended.³⁴ Management should be decided according to the reviewed diagnosis. If the cytological interpretation of HSIL is upheld, excision of the TZ is recommended provided the woman is not pregnant.¹² If colposcopy is unsatisfactory, presence of an endocervical localization of the lesion must be ruled out, therefore diagnostic excision of the TZ or conization should be performed.

The choice of treatment for women with HSIL will depend on the suspected diagnosis, the size and type of TZ, the risk of default to follow-up, age and fertility aspirations.

In a number of reporting schemes (for instance the Munich report scheme), smears suggestive of CIN2 (moderate dysplasia) are grouped with cells suggestive of CIN1 (German report scheme). In this situation, the management recommendations described in this section are restricted to a cytological report of severe dysplasia (changes suggestive of CIN3).

Management of women with glandular cytological abnormality

The cytology report should clearly define whether the cytological glandular abnormality relates to cervical or endometrial glandular cells or indicate whether the type of glandular cells cannot be clearly identified.^{1,2}

Data providing evidence. The natural history of glandular cervical lesions and the accuracy of cytology for detection of glandular intraepithelial or invasive disease are poorly documented.⁵⁸ Nevertheless, several studies indicate that the presence of atypical glandular cells (AGC) in Pap smears is associated with a high frequency of underlying high-grade (endo-) cervical neoplasia or cancer.⁵⁹⁻⁶⁵ The prevalence or short-term cumulative incidence of invasive disease (squamous, adenosquamous or endometrial cancer) varies from < 1 to 8% in follow-up series of women

with glandular Pap smear abnormalities. The predictive value is considerably higher when the presence of AGC cells is reported than in women with ASCUS or LSIL. Therefore, women with glandular cytological abnormalities require particularly careful evaluation. Repeat cytology is insufficiently sensitive to detect CGIN or invasive adenocarcinoma compared with colposcopy and endocervical and endometrial explorative methods.⁶⁶ Insufficient data are available concerning the performance of HPV DNA testing. Age is an important predictor for the origin of a glandular lesion: younger women most often have endocervical lesions, whereas endometrial carcinoma generally occurs in older women. The clinician should be aware that abnormal glandular cells may originate in the uterus, fallopian tube or ovaries and may require appropriate assessment.

Management options in case of glandular lesions. Direct referral for colposcopic, endocervical and/or endometrial exploration is indicated when a cytological result of atypical glandular cells or endocervical adenocarcinoma *in situ* (AIS) is reported. If a woman with AGC suggestive either of neoplasia or endocervical AIS has negative colposcopy, diagnostic conization should be carried out. Cold knife excision is recommended in order to avoid destruction of the margins. When the indication for referral is AGC not otherwise specified and colposcopy reveals no neoplasia, repeat cytology every 6 months for 2 years using additional endocervical brush sampling is recommended. Gynaecological exploration should be offered if one of the follow-up smears shows any degree of squamous or glandular abnormality.

When the glandular lesion is qualified as being endometrial, and if the woman is > 35 years old or if there is unexplained vaginal bleeding when the woman is < 35 years old, endometrial sampling in addition to colposcopy is indicated to exclude endometrial carcinoma.³⁴

Management of cervical smears showing endometrial cells. While cervical screening does not aim to detect endometrial carcinoma, occasionally the cervical smear will detect endometrial cells, with or without abnormality, and will contribute in some cases to the earlier diagnosis of endometrial carcinoma. For the cytopathologist there is the dilemma that a final interpretation of the findings often cannot be based on morphology alone, therefore requiring consideration of age, menstrual history, hormonal treatment (e.g.

oestrogen replacement therapy) and the presence or absence of an intrauterine device (IUD). If the history is incomplete then the cytologist will need to address this problem in the report.

Although for the assessment of cervical lesions (both squamous and glandular) repeat cytology, HPV testing and colposcopy are available and can be useful tools in deciding on further management, the options in the presence of abnormal endometrial cells are limited. In this scenario, the question is whether or not hysteroscopy and curettage of the endometrial cavity are indicated. Follow-up by repeat cervical cytology is not appropriate because the endometrial cells may be shedding intermittently.

Depending on the cytological aspect of the endometrial cells in the smear, the patient's age, the hormonal status and presence of IUD, the following management can be recommended:

1. Endometrial cells in keeping with the stage of the cycle: no need for further investigation.
2. Endometrial cells not in keeping with the stage of the cycle: no need for further investigation in young women, but may require assessment in older women.
3. Endometrial cells in women with an IUD: no need for further investigation.
4. Normal appearing endometrial cells in a post-menopausal woman: this would always warrant further assessment even if the woman is using oestrogen replacement therapy. The minimum assessment should be a vaginal ultrasound to assess endometrial thickness: if this is ≤ 4 mm, no further assessment is required. If the thickness is > 4 mm then the endometrium should be sampled either by an out-patient endometrial biopsy or preferably by endometrial biopsy or curettage or hysteroscopy and curettage.
5. Atypical endometrial cells or cytological findings suggestive of endometrial adenocarcinoma: the woman should be referred for ultrasound, hysteroscopy and biopsy or diagnostic curettage.

Acknowledgments

The content of this article is derived from the European Guidelines for Quality Assurance in Cervical Cancer Screening[®], European Communities, 2008. The full document can be downloaded from: http://bookshop.europa.eu/eubookshop/FileCache/PUBPDF/ND7007117ENC/ND7007117ENC_002.pdf. The views expressed in this article are those of the authors and

do not necessarily reflect the official position of the European Commission. The financial support of the European Commission through the *European Cervical Cancer Screening Network* and the *European Cancer Network* is gratefully acknowledged. Other funding agencies were: the DWTC/SSTC (Federal Service for Scientific, Cultural and Technical Affairs, Brussels, Belgium) and the Gynaecological Cancer Cochrane Review Collaboration (Bath, UK).

References

- Solomon D, Davey D, Kurman R *et al.* The 2001 Bethesda System: terminology for reporting results of cervical cytology. *JAMA* 2002;**287**:2114–9.
- Herbert A, Bergeron C, Wiener H *et al.* European guidelines for quality assurance in cervical cancer screening: recommendations for cervical cytology terminology. *Cytopathology* 2007;**18**:213–9.
- Arbyn M, Herbert A, Schenck U *et al.* European guidelines for quality assurance in cervical cancer screening: recommendations for collecting samples for conventional and liquid-based cytology. *Cytopathology* 2007;**18**:133–9.
- Wright TC, Sun XW, Koulos J. Comparison of management algorithms for the evaluation of women with low-grade cytologic abnormalities. *Obstet Gynecol* 1995;**85**:202–10.
- Arbyn M, Buntinx F, Van Ranst M *et al.* Virologic versus cytologic triage of women with equivocal Pap smears: a meta-analysis of the accuracy to detect high-grade intraepithelial neoplasia. *J Natl Cancer Inst* 2004;**96**:280–93.
- Arbyn M, Dillner J, Van Ranst M *et al.* Re: Have we resolved how to triage equivocal cervical cytology? *J Natl Cancer Inst* 2004;**96**:1401–2.
- Hinselmann H. Verbesserung der Inspektionsmöglichkeiten von Vulva, Vagina und Portio. *Munch Med Wochenschr* 1925;**72**:1733–42.
- Jordan JA. Colposcopy in the diagnosis of cervical cancer and precancer. *Clin Obstet Gynecol* 1985;**12**:67–76.
- Sellors JW, Sankaranarayanan R. *Colposcopy and Treatment of Cervical Intraepithelial Neoplasia: A Beginners' Manual*. Lyon: IARC; 2003:1–132.
- Walker P, Dexeus S, De Palo G *et al.* International terminology of colposcopy: an updated report from the International Federation for Cervical Pathology and Colposcopy. *Obstet Gynecol* 2003;**101**:175–7.
- Prendiville W, Ritter J, Tatti S, Twigg L. *Colposcopy: Management Options*. Edinburgh: Saunders; 2003:1–213.
- Prendiville W. The treatment of grade 3 cervical intraepithelial neoplasia. In: *Colposcopy: Management Options*. Prendiville W, Ritter J, Tatti S, Twigg LB (eds). Edinburgh: Saunders; 2003: pp. 129–33.
- Mor-Yosef S, Lopes A, Pearson S, Monaghan M. Loop diathermy cone biopsy. *Obstet Gynecol* 1990;**73**:884–6.
- Mitchell MF, Schottenfeld D, Tortolero-Luna G, Cantor SB, Richards Kortum R. Colposcopy for the diagnosis of squamous intraepithelial lesions: a meta-analysis. *Obstet Gynecol* 1998;**91**:626–31.
- Pretorius RG, Belinson JL, Zhang WH *et al.* The colposcopic impression. Is it influenced by the colposcopist's knowledge of the findings on the referral Papanicolaou smear?. *J Reprod Med* 2001;**46**:724–8.
- Pretorius RG, Zhang WH, Belinson JL *et al.* Colposcopically directed biopsy, random cervical biopsy, and endocervical curettage in the diagnosis of cervical intraepithelial neoplasia II or worse. *Am J Obstet Gynecol* 2004;**191**:430–4.
- NHSCSP. Standards and quality in colposcopy. In: *NHS Cancer Screening Programmes, Vol. 2*. Luesley D (ed.). Sheffield: NHSCSP Publications; 1996: pp. 1–27.
- NHSCSP. *The Colposcopy Examination*. London: Cancer Research UK; 1996.
- NHSCSP. Guidance notes on the safe use of diathermy loop excision for the treatment of cervical intraepithelial neoplasia. In: *NHS Cancer Screening Programmes, Vol. 4*. Hancock CW (ed.). NHSCSP, Sheffield: NHSCSP Publications; 1997: pp. 1–10.
- NHSCSP. Colposcopy and programme management: guidelines for the NHS Cervical Screening Programme. In: *NHS Cancer Screening Programmes, Vol. 20*. Luesley D, Leeson S (eds). Sheffield, Manor House: NHSCSP publication; 2004: pp. 1–80.
- Martin M, Prendiville W. Is local anaesthetic infiltration less painful than cervical punch biopsy. A study comparing the amount of pain felt by women attending a colposcopy clinic who required a cervical punch biopsy. In: *Annual Meeting*. British Society of Colposcopy and Cervical Pathology (ed.). Edinburgh: BSCCP; 2004.
- Abdel-Hady ES, Martin-Hirsch P, Duggan-Keen M *et al.* Immunological and viral factors associated with the response of vulval intraepithelial neoplasia to photodynamic therapy. *Cancer Res* 2001;**61**:192–6.
- Cartier R, Cartier I. *Practical Colposcopy*, 3rd edn. Paris: Laboratoire Cartier; 1993.
- Prendiville W, Davies R, Berry PJ. A low voltage diathermy loop for taking cervical biopsies. A qualitative comparison with punch biopsy forceps. *Br J Obstet Gynaecol* 1986;**93**:773–6.
- Anderson MC, Jordan JA, Morse AR, Sharpe F. *Integrated Colposcopy*, 2nd edn. London: Chapman and Hall; 1996.
- Ismail SM, Colclough AB, Dinnen JS *et al.* Observer variation in histopathological diagnosis and grading of cervical intraepithelial neoplasia. *BMJ* 1989;**298**:707–10.
- Stoler MH, Schiffman MA. Interobserver reproducibility of cervical cytologic and histologic interpretations. *JAMA* 2001;**285**:1500–5.

28. Horvat R, Jordan J, Herbert A, Wiener H. Chapter 5: Techniques and quality assurance guidelines for histopathology. In: *European Guidelines for Quality Assurance in Cervical Cancer Screening*. Arbyn M, Anttila A, Jordan J *et al.* (eds). Luxembourg: Office for Official Publications of the European Communities; 2008: pp. 173–89.
29. Weitzman GA, Korhonen MO, Reeves KO *et al.* Endocervical brush cytology. An alternative to endocervical curettage?. *J Reprod Med* 1988;**33**:677–83.
30. Andersen W, Frierson H, Barber S *et al.* Sensitivity and specificity of endocervical curettage and the endocervical brush for the evaluation of the endocervical canal. *Am J Obstet Gynecol* 1988;**159**:702–7.
31. Hoffman MS, Sterghos S Jr, Gordy LW, Gunasekar D. Evaluation of the cervical canal with the endocervical brush. *Obstet Gynecol* 1993;**82**:573–7.
32. Mogensen ST, Bak M, Dueholm M *et al.* Cytobrush and endocervical curettage in the diagnosis of dysplasia and malignancy of the uterine cervix. *Acta Obstet Gynecol Scand* 1997;**76**:69–73.
33. Gath DH, Hallam N, Mynors-Wallis L, Day A, Bond SAK. Emotional reactions in women attending a UK colposcopic clinic. *J Epidemiol Community Health* 1995;**49**:79–83.
34. Wright TC, Cox JT, Massad LS, Wilkinson EJ. 2001 Consensus guidelines for the management of women with cervical cytological abnormalities. *JAMA* 2002;**287**:2120–9.
35. Anttila A, Ronco G, Lynge E *et al.* Chapter 2: Epidemiological guidelines for quality assurance in cervical cancer screening. In: *European Guidelines for Quality Assurance in Cervical Cancer Screening*. Arbyn M, Anttila A, Jordan J *et al.* (eds). Luxembourg: Office for Official Publications of the European Communities; 2008: pp. 11–52.
36. Arbyn M, Dillner J, Schenck U *et al.* Chapter 3: Methods for screening and diagnosis. In: *European Guidelines for Quality Assurance in Cervical Cancer Screening*. Arbyn M, Anttila A, Jordan J *et al.* (eds). Luxembourg: Office for Official Publications of the European Communities; 2008: pp. 69–152.
37. Melnikow J, Nuovo J, Willan AR, Chan BK, Howell LP. Natural history of cervical squamous intraepithelial lesions : a meta-analysis. *Obstet Gynecol* 1998;**92**:727–35.
38. Nygard JF, Skare GB, Thoresen SO. The cervical cancer screening programme in Norway, 1992–2000: changes in Pap smear coverage and incidence of cervical cancer. *J Med Screen* 2002;**9**:86–91.
39. ASCUS-LSIL Triage Study Group. Results of a randomized trial on the management of cytology interpretations of atypical squamous cells of undetermined significance. *Am J Obstet Gynecol* 2003;**188**:1383–92.
40. Morin C, Bariati C, Bouchard C *et al.* Managing atypical squamous cells of undetermined significance in Papanicolaou smears. *J Reprod Med* 2001;**46**:799–805.
41. Solomon D, Schiffman MA, Tarone B. Comparison of three management strategies for patients with atypical squamous cells of undetermined significance (ASCUS): baseline results from a randomized trial. *J Natl Cancer Inst* 2001;**93**:293–9.
42. Arbyn M, Sasieni P, Meijer CJ *et al.* Chapter 9: Clinical applications of HPV testing: a summary of meta-analyses. *Vaccine* 2006;**24**(Suppl. 3):78–89.
43. Cox JT, Schiffman MA, Solomon D. Prospective follow-up suggests similar risk of subsequent cervical intraepithelial neoplasia grade 2 or 3 among women with cervical intraepithelial neoplasia grade 1 or negative colposcopy and directed biopsy. *Am J Obstet Gynecol* 2003;**188**:1406–12.
44. Guido R, Schiffman MA, Solomon D, Burke L. Postcolposcopy management strategies for women referred with low-grade squamous intraepithelial lesions or human papillomavirus DNA-positive atypical squamous cells of undetermined significance: a two-year prospective study. *Am J Obstet Gynecol* 2003;**188**:1401–5.
45. Cuzick J, Szarewski A, Cubie H *et al.* Management of women who test positive for high-risk types of human papillomavirus: the HART study. *Lancet* 2003; **362**:1871–6.
46. Coleman D, Day N, Douglas G *et al.* European guidelines for quality assurance in cervical cancer screening. Europe against cancer programme. *Eur J Cancer* 1993; **29A**(Suppl. 4):S1–38.
47. Sawaya GF. A 21-year-old woman with atypical squamous cells of undetermined significance. *JAMA* 2005;**294**:2210–8.
48. Holowaty P, Miller AB, Rohan T, To T. Natural history of dysplasia of the uterine cervix. *J Natl Cancer Inst* 1999;**91**:252–8.
49. Arbyn M, Paraskevaidis E, Martin-Hirsch P, Prendiville W, Dillner J. Clinical utility of HPV DNA detection: triage of minor cervical lesions, follow-up of women treated for high-grade CIN. An update of pooled evidence. *Gynecol Oncol* 2005;**99**(Suppl. 3):7–11.
50. Bergeron C, Jeannel D, Poveda J, Cassonnet P, Orth G. Human papillomavirus testing in women with mild cytologic atypia. *Obstet Gynecol* 2000;**95**:821–7.
51. Ferris DG, Wright TC Jr, Litaker MS *et al.* Comparison of two tests for detecting carcinogenic HPV in women with Papanicolaou smear reports of ASCUS and LSIL. *J Fam Pract* 1998;**46**:136–41.
52. Nobbenhuis MAE, Walboomers JM, Helmerhorst TJM *et al.* Relation of human papillomavirus status to cervical lesions and consequences for cervical-cancer screening: a prospective study. *Lancet* 1999; **354**:20–5.
53. Nobbenhuis MA, Helmerhorst TJ, van den Brule AJ *et al.* Cytological regression and clearance of high-risk human papillomavirus in women with an abnormal cervical smear. *Lancet* 2001;**358**:1782–3.
54. Remmink AJ, Walboomers JM, Helmerhorst TJM *et al.* The presence of persistent high-risk HPV genotypes in

- dysplastic cervical lesions is associated with progressive disease: natural history up to 36 months. *Int J Cancer* 1995;**61**:306–11.
55. Van Duin M, Snijders PJ, Schrijnemakers HF *et al.* Human papillomavirus 16 load in normal and abnormal cervical scrapes: an indicator of CIN II/III and viral clearance. *Int J Cancer* 2002;**98**:590–5.
 56. Schlecht NF, Platt RW, Duarte-Franco E *et al.* Human papillomavirus infection and time to progression and regression of cervical intraepithelial neoplasia. *J Natl Cancer Inst* 2003;**95**:1336–43.
 57. ASCUS-LSIL Triage Study Group. A randomized trial on the management of low-grade squamous intraepithelial lesion cytology interpretations. *Am J Obstet Gynecol* 2003;**188**:1393–400.
 58. Kurman RJ, Henson DE, Herbst AL *et al.* Interim guidelines for management of abnormal cervical cytology. *JAMA* 1994;**271**:1866–9.
 59. Taylor RR, Guerrieri JP, Nash JD, Henry MR, O'Connor DM. Atypical cervical cytology. Colposcopic follow-up using the Bethesda System. *J Reprod Med* 1993;**38**:443–7.
 60. Duska LR, Flynn CF, Chen A, Whall-Strojwas D, Goodman A. Clinical evaluation of atypical glandular cells of undetermined significance on cervical cytology. *Obstet Gynecol* 1998;**91**:278–82.
 61. Kennedy AW, Salmieri SS, Wirth SL *et al.* Results of the clinical evaluation of atypical glandular cells of undetermined significance (AGCUS) detected on cervical cytology screening. *Gynecol Oncol* 1996;**63**:14–8.
 62. Ronnett BM, Manos M, Ransley JE *et al.* Atypical glandular cells of undetermined significance (AGUS): cytopathologic features, histopathologic results, and human papillomavirus DNA detection. *Hum Pathol* 1999;**30**:816–25.
 63. Eddy GL, Strumpf KB, Wojtowycz MA, Piraino PS, Mazur MT. Biopsy findings in five hundred thirty-one patients with atypical glandular cells of uncertain significance as defined by the Bethesda system. *Am J Obstet Gynecol* 1997;**177**:1188–95.
 64. Soofer SB, Sidawy MK. Atypical glandular cells of undetermined significance: clinically significant lesions and means of patient follow-up. *Cancer* 2000;**90**:207–14.
 65. Valdini A, Vaccaro C, Pechinsky G, Abernathy V. Incidence and evaluation of an AGUS Papanicolaou smear in primary care. *J Am Board Fam Pract* 2001;**14**:172–7.
 66. Kim TJ, Kim HS, Park CT *et al.* Clinical evaluation of follow-up methods and results of atypical glandular cells of undetermined significance (AGUS) detected on cervicovaginal Pap smears. *Gynecol Oncol* 1999;**73**:292–8.